



Published in final edited form as:

Pract Neurol. 2015 February ; 15(1): 42–44. doi:10.1136/practneurol-2014-000913.

Cerebrospinal fluid shunt-induced chorea: case report and review of the literature on shunt-related movement disorders

Claudio M de Gusmão¹, Aaron L Berkowitz², Albert Y Hung², and M Brandon Westover²

¹Neurology Department, Boston Children's Hospital, Boston, Massachusetts, USA

²Neurology Department, Massachusetts General Hospital, Boston, Massachusetts, USA

INTRODUCTION

Cerebrospinal fluid (CSF) diversion by shunting provides effective management of hydrocephalus.¹ However, complication rates of CSF shunts range from 5% to 50%.^{1–3} Most common are shunt infections and mechanical failures; these may lead either to underdrainage (with re-emergence of hydrocephalus) or over-drainage (with intracranial hypotension and its potential complications, eg, sub-dural hematoma).^{3,4} Misplacement and migration of shunt catheters may cause seizures, intracerebral haemorrhage, and/ or focal neurologic deficits, such as hemiparesis.¹² We report a case of hemichorea after CSF shunt placement, and review the literature on CSF shunt-related movement disorders.

CASE REPORT

A 20-year-old woman with congenital hydrocephalus treated by CSF shunting presented with a purulent discharge from the site of a recent shunt revision and had a shunt infection. Her previous ventriculoperitoneal shunt was removed and a new ventriculopleural shunt was placed through a left occipital approach. There were no recent medication changes. Five days later, she developed debilitating involuntary choreoathetotic movements of the right upper and lower limbs (see online supplementary video 1), interfering with feeding and walking. Her examination, apart from the involuntary movements, was normal, with no rigidity, tremor, weakness, or ataxia. Her serum electrolytes were normal. CT scan of head showed that the shunt catheter tip penetrated the ventricular wall into the brain parenchyma (figure 1); MR scan of brain showed that its tip abutted the posterior aspect of the putamen (figure 2). There was no worsening of hydrocephalus, stroke, or haemorrhage. The shunt was surgically repositioned. Her choreoathetosis started improving immediately postoperatively,

Correspondence to: Dr Claudio M de Gusmão, Neurology Department, Boston Children's Hospital, 300 Longwood Ave, Fegan 11, Boston, MA 02115, USA; claudio.degusmao@childrens.harvard.edu.

Contributors: CMdG: original idea, drafted the manuscript, edited images, performed literature review. ALB: original idea, revised the original manuscript and images, critical appraisal of literature review. AYH and MBW: critical review and modifications of the final manuscript; appraisal of literature review and associated media.

Competing interests: None.

Patient consent: Obtained.

Provenance and peer review: Not commissioned. Externally peer reviewed. This paper was reviewed by Tony Amato-Watkins, Cardiff, UK.

and had largely resolved spontaneously at 2 weeks when she was discharged to rehabilitation (see online supplementary video 2)

DISCUSSION

Movement disorders related to cerebrospinal fluid (CSF) shunting are rare, though parkinsonism, ataxia, ballism and torticollis may occasionally occur (table 1). We could find only one previous report of shunt-related hemichorea, which, as here, resolved after shunt repositioning.⁵

The mechanism of ventriculoperitoneal (VP) shunt-related movement disorders has been attributed to ‘altered CSF dynamics’,⁶ whereby shunt obstruction causes acute hydrocephalus, with shearing, torsion, or ischaemia of striatal projections.^{7–14} Although there is a report of chorea accompanying acute hydrocephalus and resolving after shunting, in that case the movements were generalised and presumed secondary to caudate head compression by the dilated lateral ventricle.¹⁵ In our case, the movement disorder probably resulted from direct striatal irritation by the shunt catheter itself, as the movement disorder emerged in the setting of normal shunt function with no radiological evidence of worsening hydrocephalus, and promptly resolved after shunt repositioning.

CONCLUSION

Hemichorea is an unusual complication of CSF shunt placement. Clinicians should be attentive to focal deficits including unilateral movement disorders in patients with CSF shunts, as prompt surgical intervention may alleviate debilitating neurological symptoms and minimise the risk of long-term complications.

References

1. Hdeib, A.; Cohen, AR. Hydrocephalus in children and adults. In: Ellenbogen, RG.; Abdulraf, SI.; Sekhar, LN., editors. Principles of neurological surgery. Philadelphia, PA: Elsevier; 2012. p. 105-27.
2. Aschoff A, Kremer P, Hashemi B, et al. The scientific history of hydrocephalus and its treatment. *Neurosurg Rev.* 1999; 22:67–93. discussion 94–5. <http://www.ncbi.nlm.nih.gov/pubmed/10547004>. [PubMed: 10547004]
3. Browd SR, Ragel BT, Gottfried ON, et al. Failure of cerebrospinal fluid shunts: part I: obstruction and mechanical failure. *Pediatr Neurol.* 2006; 34:83–92. [PubMed: 16458818]
4. Browd SR, Gottfried ON, Ragel BT, et al. Failure of cerebrospinal fluid shunts: part II: overdrainage, loculation, and abdominal complications. *Pediatr Neurol.* 2006; 34:171–6. [PubMed: 16504785]
5. Alakandy LM, Iyer RV, Golash A. Hemichorea, an unusual complication of ventriculoperitoneal shunt. *J Clin Neurosci.* 2008; 15:599–601. [PubMed: 18328713]
6. Prashantha DK, Netravathi M, Ravishankar S, et al. Reversible parkinsonism following ventriculoperitoneal shunt in a patient with obstructive hydrocephalus secondary to intraventricular neurocysticercosis. *Clin Neurol Neurosurg.* 2008; 110:718–21. [PubMed: 18440127]
7. Keane JR. Tremor as the result of shunt obstruction: four patients with cysticercosis and secondary parkinsonism: report of four cases. *Neurosurgery.* 1995; 37:520–2. <http://www.ncbi.nlm.nih.gov/pubmed/7501120>. [PubMed: 7501120]
8. Halterman MW, Vates GE, Riggs G. Teaching NeuroImage: tremor in aqueductal stenosis and response to endoscopic third ventriculostomy. *Neurology.* 2007; 68:E29–31. [PubMed: 17485639]

9. Jellinek EH. Not Parkinson's disease: neurologists' mistakes with a diversion into adult hydrocephalus. *Pract Neurol*. 2008; 8:322–4. [PubMed: 18796588]
10. Krauss JK, Regel JP, Droste DW, et al. Movement disorders in adult hydrocephalus. *Mov Disord*. 1997; 12:53–60. [PubMed: 8990054]
11. Lau C-I, Wang H-C, Tsai M-D, et al. Acute Parkinsonian syndrome after ventriculoperitoneal shunt malfunction caused by a roller coaster ride. *Clin Neurol Neurosurg*. 2011; 113:423–5. [PubMed: 21320745]
12. Tokunaga H, Shigeto H, Inamura T, et al. A case of severe parkinsonism induced by failure of ventriculoperitoneal shunt for aqueductal stenosis. *Rinsho Shinkeigaku*. 2003; 43:427–30. <http://www.ncbi.nlm.nih.gov/pubmed/14582370>. [PubMed: 14582370]
13. Ochiai H, Yamakawa Y, Miyata S, et al. L-dopa effective parkinsonism appeared after shunt revision of the aqueductal stenosis: report of two cases. *No To Shinkei*. 2000; 52:425–9. <http://www.ncbi.nlm.nih.gov/pubmed/10845212>. [PubMed: 10845212]
14. Akiyama TT, Tanizaki Y, Akaji K, et al. Severe parkinsonism following endoscopic third ventriculostomy for non-communicating hydrocephalus—case report. *Neurol Med Chir (Tokyo)*. 2011; 51:60–3. <http://www.ncbi.nlm.nih.gov/pubmed/21273748>. [PubMed: 21273748]
15. Voermans NC, Schutte PJ, Bloem BR. Hydrocephalus induced chorea. *J Neurol Neurosurg Psychiatry*. 2007; 78:1284–5. [PubMed: 17940178]
16. Cheshire WP, Ehle AL. Hemiparkinsonism as a complication of an Ommaya reservoir. Case report. *J Neurosurg*. 1990; 73:774–6. [PubMed: 2213168]
17. Sakurai T, Kimura A, Yamada M, et al. Rapidly progressive parkinsonism that developed one year after ventriculoperitoneal shunting for idiopathic aqueductal stenosis: a case report. *Brain Nerve*. 2010; 62:527–31. <http://www.ncbi.nlm.nih.gov/pubmed/20450100>. [PubMed: 20450100]
18. Yomo S, Hongo K, Kuroyanagi T, et al. Parkinsonism and midbrain dysfunction after shunt placement for obstructive hydrocephalus. *J Clin Neurosci*. 2006; 13:373–8. [PubMed: 16542840]
19. Rebai RM, Houissa S, Mustapha ME, et al. Akinetic mutism and parkinsonism after multiple shunt failure: case report and literature review. *J Neurol Surg A Cent Eur Neurosurg*. 2012; 73:341–6. [PubMed: 21445822]
20. Walker FO, Hunt VP. Ballism: an association with ventriculoperitoneal shunting. *Neurology*. 1990; 40:1004. <http://www.ncbi.nlm.nih.gov/pubmed/2345602>. [PubMed: 2345602]
21. Singh G, Kaif M, Ojha BK, et al. Torticollis as a late complication of ventriculoperitoneal shunt surgery. *J Clin Neurosci*. 2011; 18:865–6. [PubMed: 21507660]
22. Elliott R, Kalthorn S, Pacione D, et al. Shunt malfunction causing acute neurological deterioration in 2 patients with previously asymptomatic Chiari malformation Type I. Report of two cases. *J Neurosurg Pediatr*. 2009; 4:170–5. [PubMed: 19645553]

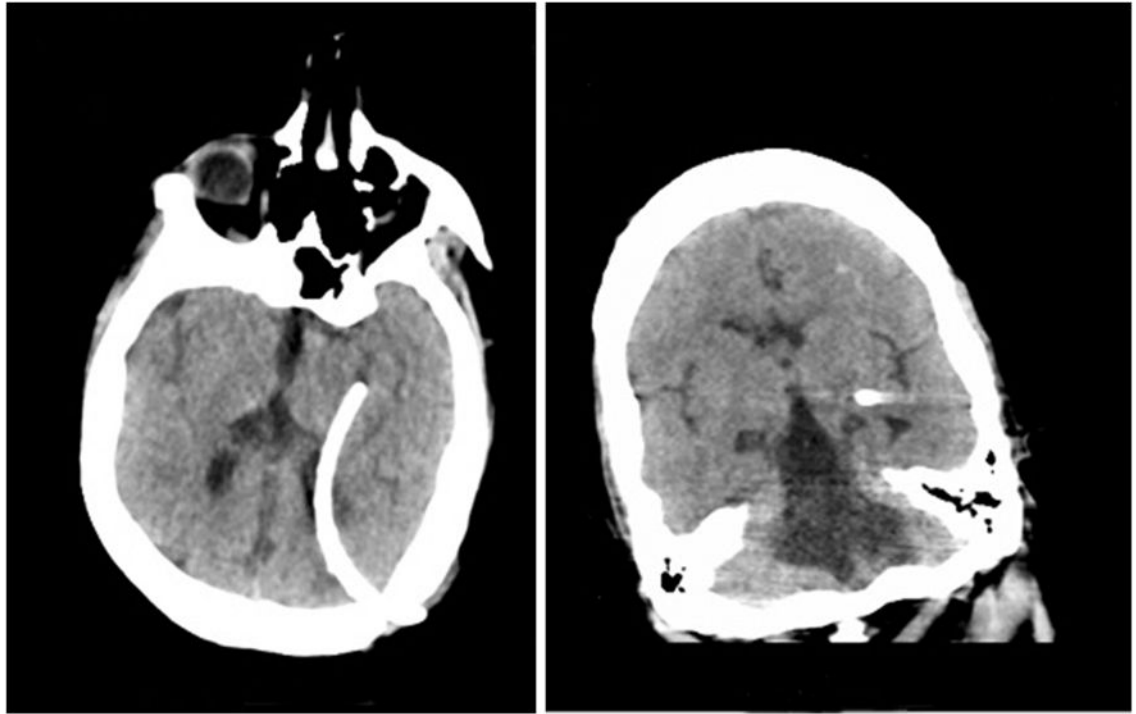


Figure 1.
CT scan of head. Axial and coronal views demonstrating catheter in the brain parenchyma.

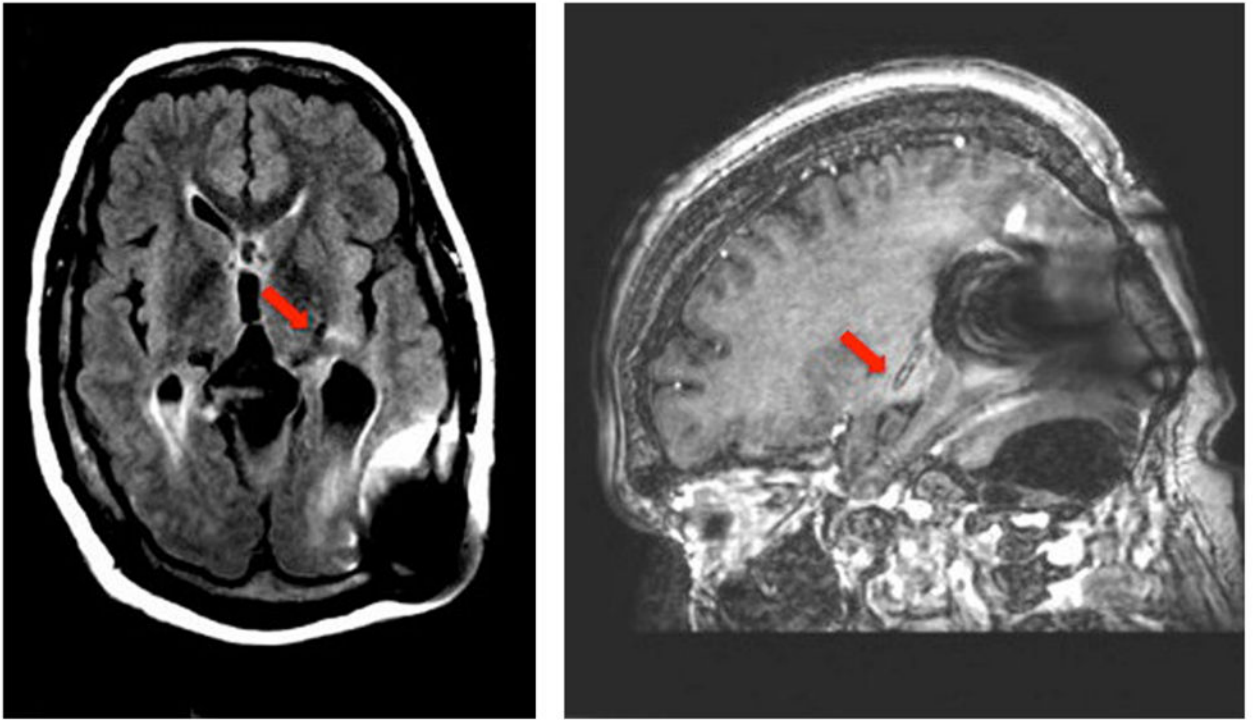


Figure 2.
MR scan of brain. Axial (T2-FLAIR) and sagittal (T1 postcontrast) views show the cerebrospinal fluid shunt catheter tip terminating in the posterior putamen (arrows).

Table 1

Movement disorders complicating shunts

Age	Type of movement	Cause of hydrocephalus	Time after shunting	Recovery and time	Mechanism	Reference
17	Parkinsonism	Pineal gland germinoma	Not reported (but 3 days after roller coaster ride)	Full, 1 month	'Shunt displacement with hydrocephalus'	Lau <i>et al</i> ¹
28	Parkinsonism	Ommaya reservoir for methotrexate injection	'Following treatment'	'Immediate after shunt insertion'	Not reported	Cheshire <i>et al</i> ¹⁶
32	Parkinsonism	'Obstructive hydrocephalus'	3 months	Improved with levodopa	'Nigrostriatal pathway concussion'	Ochiai <i>et al</i> ¹³
59	Parkinsonism	'Obstructive hydrocephalus'	3 months	Improved with levodopa	'Nigrostriatal pathway concussion'	Ochiai <i>et al</i> ¹³
38	Parkinsonism	Neurocysticercosis	3 days	Partial, 3 months	'Changes in intraventricular pressure or malpositioning of the shunt'	Pashantha <i>et al</i> ⁶
46	Parkinsonism	Aqueductal stenosis	1 year	Partial with levodopa	'Parkinsonism associated with V-P shunting'	Sakurai <i>et al</i> ⁷
64	Parkinsonism	Aqueductal stenosis	4 months	None	'Slit-ventricle syndrome'	Yomo <i>et al</i> ⁸
26	Parkinsonism	Encephalitis	7 months	Full, 2 months	'Shunt malfunction'	Tokunaga <i>et al</i> ¹²
11	Akinesia/parkinsonism	Tectal glioma	'Days'	2 weeks, Partial improvement with bromocriptine and levodopa	'Recurrent hydrocephalus and tectal glioma'	Rebai <i>et al</i> ⁹
32	Tremor/parinaud's syndrome	Neurocysticercosis	Not reported	'Several days after shunt revision'	Hydrocephalus or direct trauma to basal ganglia	Keane ⁷
68	Ballism	Normal pressure hydrocephalus	'Upon awakening from surgery'	Not reported	Not reported	Walker <i>et al</i> ²⁰
14	Torticollis	Aqueductal stenosis	12 years	Full, 1 year	'Local in the neck'	Singh <i>et al</i> ¹
14	Ataxia cerebrospinal fluid deficits	Congenital Chiari I	13 years	'Near complete', 1 week	'Positive rostral pressure gradient through stenotic foramen magnum'	Elliot <i>et al</i> ²²
24	Hemichorea	Meningitis	2 weeks	Complete, 'few days'	Not reported	Alakandy <i>et al</i>