

# Teaching the 6 EEG Spectrogram Patterns Using an Infographic

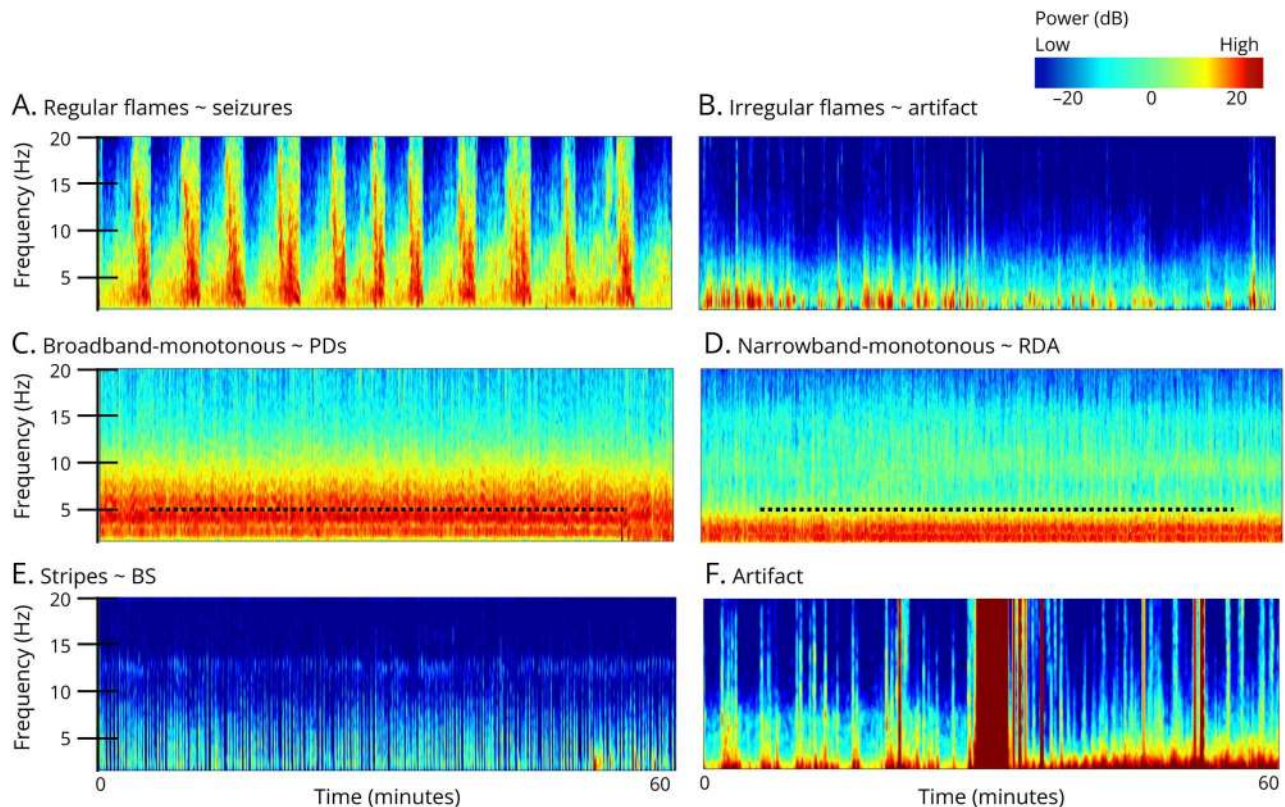
Kaley J. Marcinski Nascimento, MD, M. Brandon Westover, MD, PhD, and Fábio A. Nascimento, MD

*Neurology*® Education 2024;3:e200158. doi:10.1212/NE9.000000000200158

## Correspondence

Dr. Marcinski Nascimento  
kaleynasciminski@gmail.com

**Figure 6** EEG Spectrogram Patterns



(A) Regular flames ~ seizures: abrupt segments with high power and bandwidth rising up from delta range. (B) Irregular flames ~ artifact: choppy and irregular flame-like morphology. (C) Broadband-monotonous ~ periodic discharges: sustained high power across broad range extending to >5 Hz. (D) Narrowband-monotonous ~ rhythmic delta activity: sustained high power restricted to <5 Hz. (E) Stripes ~ burst suppression: alternating low and high power. (F) Artifact: irregular high-power signals across most or all frequencies. ~ = suggestive of; BS = burst suppression; PDs = periodic discharges; RDA = rhythmic delta activity.

Quantitative EEG allows faster analysis of continuous long-term EEG recordings—namely in the critical care setting. A standardized, user-friendly nomenclature for EEG spectrograms including 6 patterns has been proposed (Figure).<sup>1</sup> With high inter-rater agreement among electroencephalographers, this framework serves as a valuable tool to aid in rapid and accurate identification of seizures and ictal-interictal continuum patterns<sup>2</sup> by experts and nonexperts—including bedside providers. Confirmation on raw EEG should always be

From the Department of Neurology (K.J.M.N., F.A.N.), Washington University School of Medicine, St. Louis, MO; and Department of Neurology (M.B.W.), Beth Israel Deaconess Medical Center, Boston, MA.

Go to [Neurology.org/NE](https://www.neurology.org/NE) for full disclosures. Funding information and disclosures deemed relevant by the authors, if any, are provided at the end of the article.

This is an open access article distributed under the terms of the Creative Commons Attribution License 4.0 (CC BY), which permits unrestricted use, distribution, and reproduction in any medium, provided the original work is properly cited.

pursued. Educators may use Figure and video-based resources<sup>e1</sup> to teach and illustrate each of the 6 emblematic EEG spectrogram patterns.

## Study Funding

No targeted funding reported.

## Disclosure

The authors report no disclosures. Go to [Neurology.org/NE](https://www.neurology.org/NE) for full disclosures.

## Publication History

Received by *Neurology: Education* July 9, 2024. Accepted in final form August 26, 2024. Submitted and externally peer reviewed. The handling editor was Roy E. Strowd III, MD, MEd, MS.

## Appendix Authors

Name	Location	Contribution
<b>Kaley J. Marcinski Nascimento, MD</b>	Department of Neurology, Washington University School of Medicine, St. Louis, MO	Drafting/revision of the manuscript for content, including medical writing for content; major role in the acquisition of data; study concept or design; analysis or interpretation of data

## Appendix (continued)

Name	Location	Contribution
<b>M. Brandon Westover, MD, PhD</b>	Department of Neurology, Beth Israel Deaconess Medical Center, Boston, MA	Drafting/revision of the manuscript for content, including medical writing for content; major role in the acquisition of data; study concept or design; analysis or interpretation of data
<b>Fábio A. Nascimento, MD</b>	Department of Neurology, Washington University School of Medicine, St. Louis, MO	Drafting/revision of the manuscript for content, including medical writing for content; major role in the acquisition of data; study concept or design; analysis or interpretation of data

## References

- Hirsch LJ, Fong MWK, Leitinger M, et al. American Clinical Neurophysiology Society's standardized critical care EEG terminology: 2021 version. *J Clin Neurophysiol.* 2021;38(1):1-29. doi:10.1097/WNP.0000000000000806
  - Zafar SF, Amorim E, Williamsom CA, et al. A standardized nomenclature for spectrogram EEG patterns: inter-rater agreement and correspondence with common intensive care unit EEG patterns. *Clin Neurophysiol.* 2020;131(9):2298-2306. doi:10.1016/j.clinph.2020.05.032
- eReference is available as supplemental digital content at [Neurology.org/NE](https://www.neurology.org/NE).